

A phase 1/2 study of genetically-corrected, collagen VII expressing autologous human dermal fibroblasts injected into the skin of patients with recessive dystrophic epidermolysis bullosa (RDEB)

MP Marinkovich^{1, 4*}, A Lane^{1,3}, K Sridhar¹, D Keene², A Malyala³, M Spellman³, J Maslowski³

¹Stanford University School of Medicine, Stanford, CA ²Shriners Hospital for Children, Portland, OR ³Castle Creek Pharma, Exton, PA ⁴Veterans Affairs Medical Center, Palo Alto, Stanford, CA
*mmp@stanford.edu

INTRODUCTION & BACKGROUND

Recessive dystrophic epidermolysis bullosa (RDEB) is an inherited genetic skin blistering disease caused by mutations in the *COL7A1* gene encoding type VII collagen (COL7) that results in dermal-epidermal separation. Current therapy for RDEB is limited to palliative wound care as there are no curative treatments and no approved drugs for RDEB. We report the results of the ongoing Phase 1/2 clinical trial of genetically-corrected, COL7 expressing autologous human dermal fibroblasts (FCX-007) for the treatment of RDEB wounds (NCT02810951). The primary objective of this study is to evaluate the safety of intradermal injection of FCX-007. Secondary objectives are to evaluate clinical efficacy via percent wound healing compared to baseline in chronic wounds and evaluate pharmacology via immunofluorescence (IF) and immunoelectron microscopy (IEM).

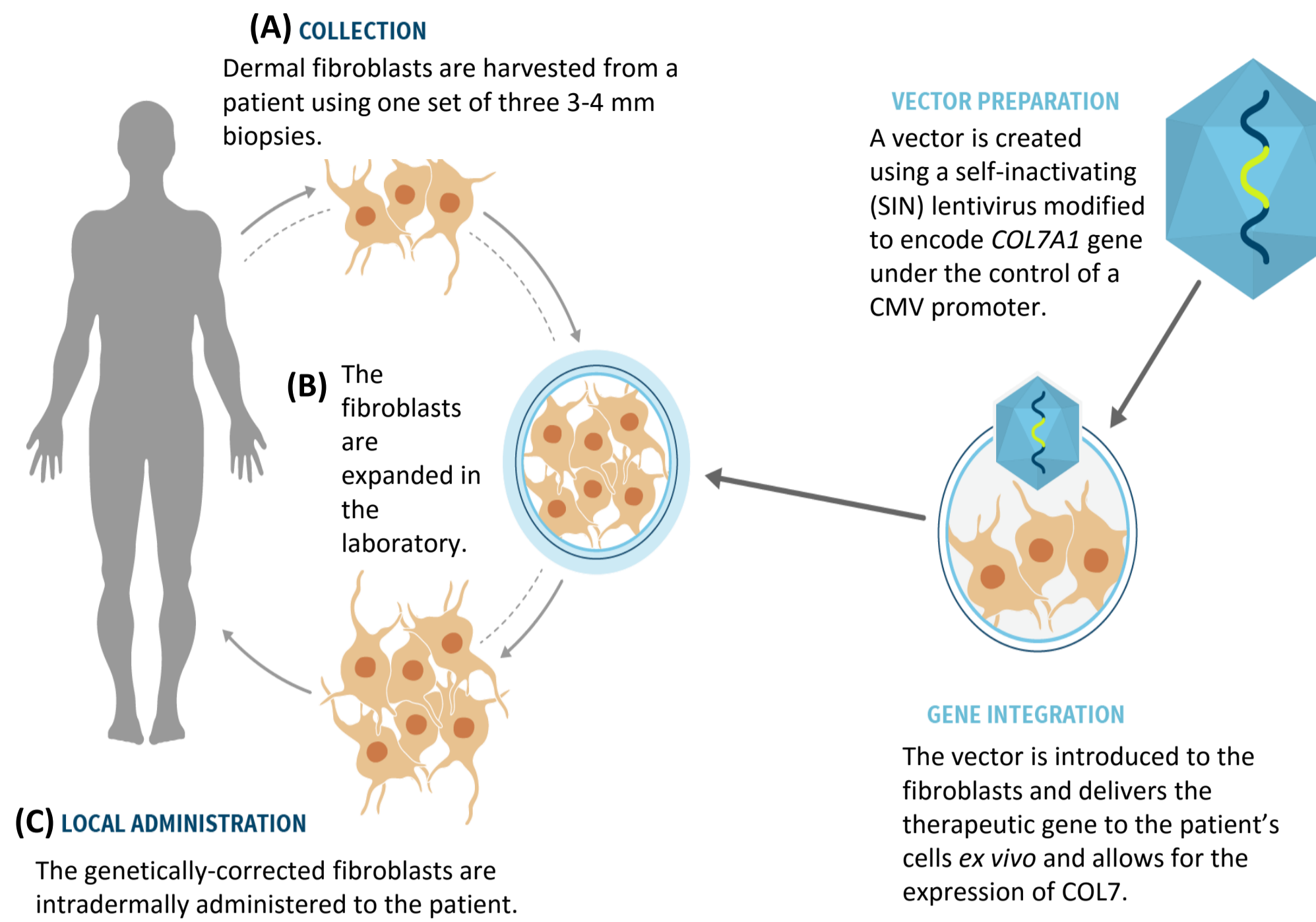
DEMOGRAPHICS

Table 1. Clinical Characteristics of Subjects

Subject #	101	102	103	104	105	106
Age at enrollment	26	21	33	38	33	9
Sex	M	M	M	F	M	M
<i>COL7A1</i> Mutation 1	5048_5051 dup (GAAA) (exon 54)	5048_5051 dup (GAAA) (exon 54)	6527dupC (exon 80)	356_357 delCA	8440 C>T (homozygous)	1573 C>T
<i>COL7A1</i> Mutation 2	90delC (exon 2)	90delC (exon 2)	7485 + 5 G>A (intron 98)	2017G>T	8440 C>T (homozygous)	6527dupC
COL7 Expression (IF)	Negative	Negative	Negative	Negative	Negative	Negative
COL7 Expression (WB)	NC-1 positive	NC-1 positive	NC-1 positive	NC-1 negative (null)	NC-1 positive	NC-1 positive
Electron Microscopy	no AF/sublamina densa split	no AF/sublamina densa split	no AF/sublamina densa split	no AF/sublamina densa split	no mature AF	no AF/sublamina densa split
COL7 Autoantibodies	Negative	Negative	Negative	Negative	Negative	Negative
History of SCC	No	No	No	Yes	Yes	No

AF anchoring fibrils; IF immunofluorescence; NC-1 non-collagenous-1; SCC squamous cell carcinoma; WB Western blot

Figure 1. Gene-corrected Autologous Fibroblasts (FCX-007)



(A) Fibroblasts isolated from RDEB patient skin biopsy. (B) Fibroblasts expanded and transduced with SIN lentiviral vector encoding *COL7A1*. (C) Genetically-corrected autologous fibroblasts (FCX-007) ready for intradermal administration.

METHODS

Six subjects, five adults and one child, with severe generalized RDEB (ages 9 to 38 at age of enrollment) were dosed with FCX-007. Chronic wounds were targeted and confirmed in a 12-week pre-injection monitoring period. The subjects carried various *COL7A1* mutations resulting in undetectable COL7 expression by immunofluorescence microscopy (IF) and a lack of anchoring fibrils (AF) by immunoelectron microscopy (IEM) (Table 1). The therapy was administered in the margins of and across targeted chronic wounds, ranging in size from 4.3 to 34.1 cm², as well as in separate intact skin sites. Persistent non-healing wounds were targeted to assess efficacy of wound healing and pharmacology via IF and IEM. All six subjects received a single treatment session at baseline. Four subjects received a second treatment session at 52, 25, 12, and 4 weeks post-baseline administration; subjects 0102, 0103, 0105 and 0106, respectively.

RESULTS

Safety

Interim data from the six subjects show that FCX-007 was well tolerated up to 52 weeks post-administration with no antibody response to COL7 detected after initial or repeat administration. No replication-competent lentivirus (RCL) and no COL7 antibody responses have been noted in serum samples from subjects, including one subject with a negative NC-1 genotype.

Three subjects treated with FCX-007 had serious adverse events (SAE): Two subjects had SAEs of squamous cell carcinoma (SCC) progression at untreated sites (unrelated to FCX-007), one with fatal outcome. One subject was hospitalized with influenza approximately one-month post-treatment (unrelated to FCX-007).

The injection procedure was well tolerated by all subjects, with occasional reports of short-lived erythema and injection site discoloration (related to FCX-007).

Efficacy

Table 2. Treated Wound Healing Data

	Observed % Healing (Number of Wounds)			
	Week 4	Week 12	Week 25	Week 52
≥50% Wound Healing	80% (8/10)	90% (9/10)	75% (3/4)	83% (5/6)
≥75% Wound Healing	70% (7/10)	80% (8/10)	75% (3/4)	67% (4/6)
Complete Wound Healing	40% (4/10)	80% (8/10)	75% (3/4)	50% (3/6)

Table 3. Untreated Wound Healing Data

	Observed % Healing (Number of Wounds)			
	Week 4	Week 12	Week 25	Week 52
≥50% Wound Healing	20% (2/10)	44% (4/9)	50% (2/4)	33% (2/6)
≥75% Wound Healing	10% (1/10)	11% (1/9)	0% (0/4)	16% (1/6)
Complete Wound Healing	0% (0/10)	0% (0/9)	0% (0/4)	16% (1/6)

Digital images captured and wound tracings performed. Skin tattoos and transparent overlays were used as landmarks. Best matched untreated wound was also monitored in conjunction with each treated wound on the same patient. Wounds were assessed for percent wound healing compared to baseline. Week 52 visit has not occurred for subject 0106. The number of wounds observed for wound healing decreased over time due to missed clinic visits and missing data. Vector presence was detected by PCR 25 weeks after injection into intact and wound treated skin.

Figure 2. Subject 0106 Treated Wound

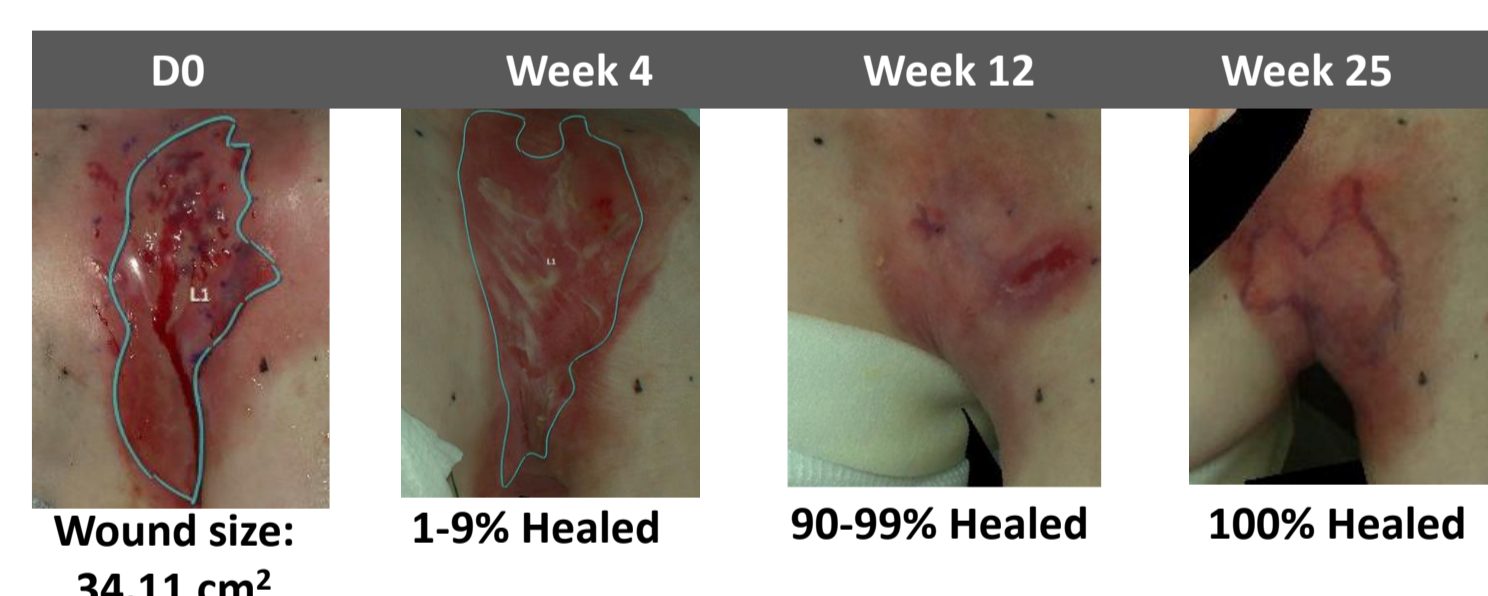
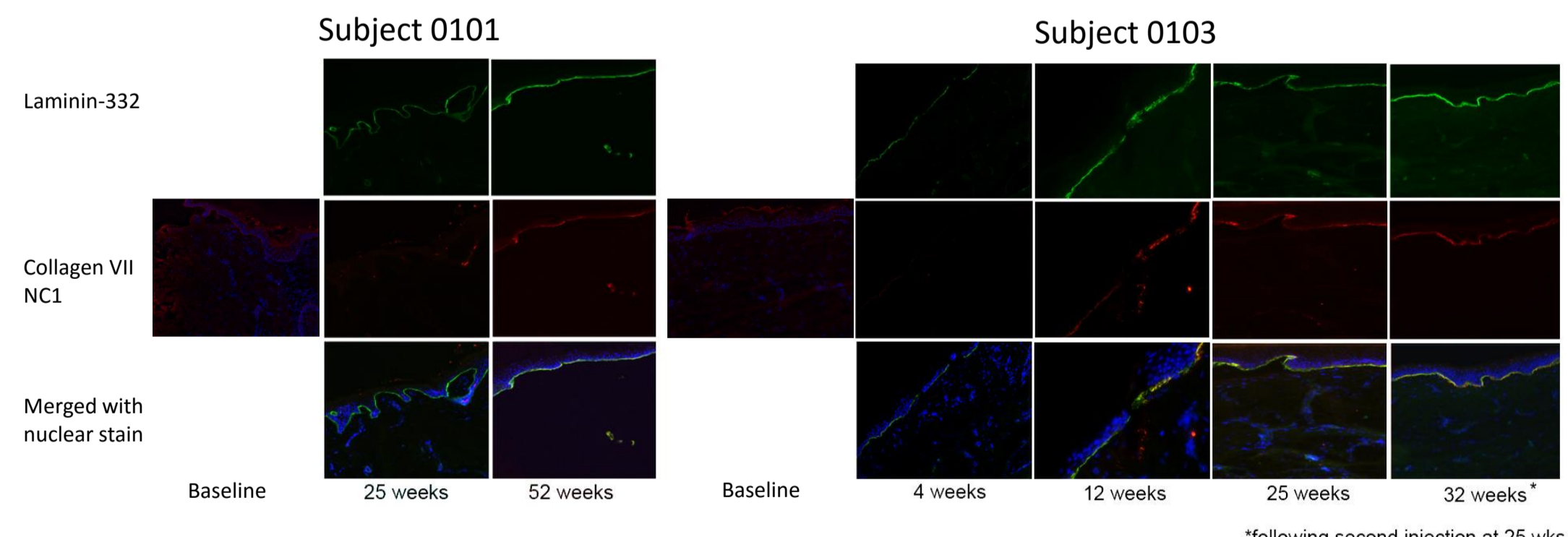
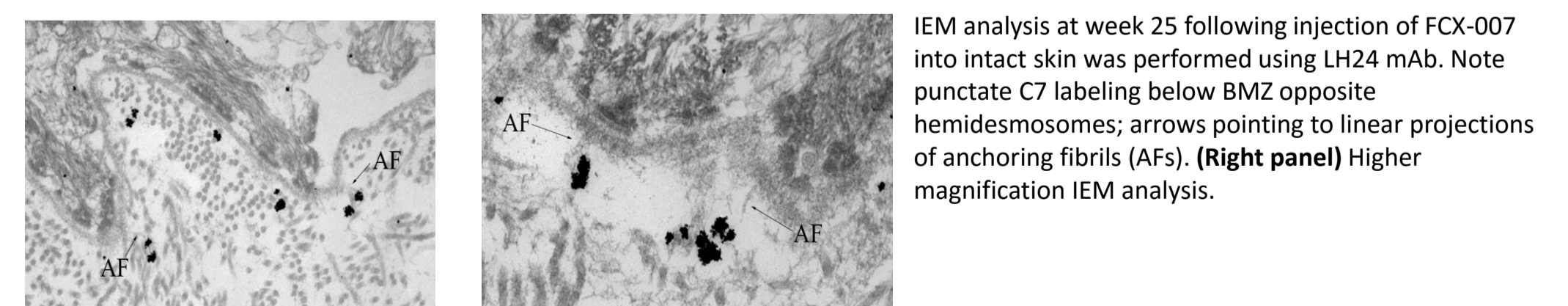


Figure 3. C7 Expression Following Injection FCX-007



Linear C7 protein was detected by IF at the dermal-epidermal junction at 25 weeks and 52 weeks following injection into skin of subject 0101, and at 12 and 25 weeks in subject 0103. At 25 weeks, a second injection of FCX-007 was performed for subject 0103, and at 32 weeks, linear robust C7 expression was noted at the reinjection site.

Figure 4. C7 Ultrastructural Localization



CONCLUSIONS

In this interim data set, FCX-007 was well tolerated up to 52 weeks post-administration. Injections of both chronically wounded and intact skin were well tolerated without safety issues, including a lack of immune or RCL related events. Positive wound healing trends and pharmacology signals were observed for up to 52 weeks of testing. These results informed design of the phase 3 DEFI-RDEB study (NCT04213261).